

## Cranial deformation and trephination in the Middle East

B. Arensburg, I. Hershkovitz

---

**Citer ce document / Cite this document :**

Arensburg B., Hershkovitz I. Cranial deformation and trephination in the Middle East. In: Bulletins et Mémoires de la Société d'anthropologie de Paris, XIV<sup>e</sup> Série. Tome 5 fascicule 3, 1988. pp. 139-150;

doi : <https://doi.org/10.3406/bmsap.1988.1669>

[https://www.persee.fr/doc/bmsap\\_0037-8984\\_1988\\_num\\_5\\_3\\_1669](https://www.persee.fr/doc/bmsap_0037-8984_1988_num_5_3_1669)

---

Fichier pdf généré le 09/05/2018

## Résumé

PRATIQUE DE TRÉPANATION ET DE DÉFORMATION CRANIENNE DANS L'ANCIEN MOYEN ORIENT Résumé. — La pratique de trépanation et de déformation crânienne dans l'ancien Moyen Orient fait l'objet de cet article. Ces deux « traitements » ont probablement débuté au Néolithique ou au Chalcolithique. La déformation du crâne devient rare après le Néolithique, alors que la fréquence des trépanations augmente surtout pendant la période romaine. L'ouverture artificielle du crâne est pratiquée de deux manières différentes : soit par incision circulaire (pour la période la plus ancienne comme pour la période romaine), soit par incision angulaire (âge du Fer et période byzantine). Cette dernière technique de trépanation a probablement son origine en Afrique du Nord. Le rôle des « médecins » juifs dans la pratique de ces opérations durant l'époque romaine est par ailleurs discutée.

## Abstract

Summary. — The practice of trephination and deforming the human skull in the ancient Middle East is reported here. Both « treatments » seem to have occur during the Neolithic and Chalcolithic periods. After the Neolithic, cranial deformation became relatively rare while the frequency of threphination continued and even increased in Roman times. The « surgical operation » of the skull was performed by two different techniques : 1) a « round » incision of the bone, found in all historic periods ; 2) an « angular » incision confined to the Iron and Byzantine periods at Lachish and Timna. The latter type seems to be « imported » from North Africa. The role of Jewish « doctors » in performing these cultural practices during the Roman period is discussed.

## CRANIAL DEFORMATION AND TREPHINATION IN THE MIDDLE EAST

B. ARENSBURG and I. HERSHKOVITZ (\*)

*Summary.* — The practice of trephination and deforming the human skull in the ancient Middle East is reported here. Both « treatments » seem to have occurred during the Neolithic and Chalcolithic periods. After the Neolithic, cranial deformation became relatively rare while the frequency of trephination continued and even increased in Roman times. The « surgical operation » of the skull was performed by two different techniques : 1) a « round » incision of the bone, found in all historic periods ; 2) an « angular » incision confined to the Iron and Byzantine periods at Lachish and Timna. The latter type seems to be « imported » from North Africa. The role of Jewish « doctors » in performing these cultural practices during the Roman period is discussed.

### PRATIQUE DE TRÉPANATION ET DE DÉFORMATION CRANIENNE DANS L'ANCIEN MOYEN ORIENT

*Résumé.* — La pratique de trépanation et de déformation crânienne dans l'ancien Moyen Orient fait l'objet de cet article. Ces deux « traitements » ont probablement débuté au Néolithique ou au Chalcolithique. La déformation du crâne devient rare après le Néolithique, alors que la fréquence des trépanations augmente surtout pendant la période romaine. L'ouverture artificielle du crâne est pratiquée de deux manières différentes : soit par incision circulaire (pour la période la plus ancienne comme pour la période romaine), soit par incision angulaire (âge du Fer et période byzantine). Cette dernière technique de trépanation a probablement son origine en Afrique du Nord. Le rôle des « médecins » juifs dans la pratique de ces opérations durant l'époque romaine est par ailleurs discutée.

### I. — INTRODUCTION

The purpose of the present paper is to review surgical and ritual practices on living peoples in ancient times in the Middle East in general and in Israel in particular. First will be trephination, a surgical opening of the skull, followed by head deformation. Such a review will be, it is hoped, a pertinent contribution to the history of medicine in the region.

#### 1) Trephination

Trephination (trepanation or trepanning), is one of the most ancient medical « treatments » on living humans. It is known from prehistoric times all over the world, and is practiced even at the present time among some tribes especially

---

(\*) Department of Anatomy and Anthropology, Sackler School of Medicine, Tel Aviv University, Ramat Aviv, Israël.

in Black Africa as reported, for example, by Lisowsky (1967) and Margetts (1967). As a surgical *treatment*, trephination appears to have had a remarkable post-operative survival rate, testified by hundreds of skulls with healed wounds in crania from many regions of the world, and especially in pre-Columbian America (Hrdlicka, 1897 ; Stewart, 1958).

In the Middle East, trephined skulls have been found, for example, in Egypt, Sudan, Israel, Iran and Turkey. The oldest trephined skulls found in the area are most probably those from the Chalcolithic period from South Sinai (Hershkovitz, 1987), as well as from Israel in the Early Bronze Age in Arad (P. Smith, personal communication) and from the Chalcolithic — Early Bronze Age in Azur (our unpublished material). A Neolithic trephined skull has also been mentioned by Kurth and Rehrer-Ertl (1981) from a site at Jericho, but no further information is available on this specimen other than it presents a healed wound. Trephined skulls have also been found presenting round, some with healed, holes in the scalp during the Middle Bronze Age at Jericho in the Jordan Valley, ca. 2 000 B.C.E. (Oakley et al., 1959 ; Brothwell, 1965) and at the 18th-19th Dynasties site at Sesebi, Sudan, ca. 1 200 B.C.E. (Lisowsky, 1954).

Trephined crania are present at Iron Age sites in Lachish, Israel, ca. 700 B.C.E. (Parry, 1936) and at Sakkara, Egypt, from the 25th Dynasty, ca. 600 B.C.E. (Batrawi, 1935). In the latter period a trephined skull was found in a former Assyrian colony at Kultepe, Anatolia (Senyurek, 1958), as well as in Iran at a somewhat later period (Mallin and Rathbun, 1976). Trephinations have also been found in crania from Egypt at different periods : Sakkara, Ptolomeic Age, 323-30 B.C.E. (Lisowski, 1959), the Meroitic period (Batrawi, 1935) ; in the Oman period in Alexandria, 200 C.E. (Ruffer, 1918) ; and in the Byzantine from Hesa, near Aswan, 395-638 C.E. (Wood Jones, 1910).

In Israel in the Hellenistic to Byzantine periods, cranial trephination apparently was relatively common. Thus Ferembach (1957) has described such an « operation » in a skull found at Timma, in the southern Negev, roughly dated between the end of the Iron Age and the end of the Roman period (600 B.C.E.-300 C.E.). During the Hellenistic — Roman periods (ca. 300 B.C.E.-300 C.E.), trephined skulls were found at Acco (Goldman, 1961), and at Jericho, near the Qaranthal, not far from the archaeological excavations at the Tell (Ghannan, 1963 ; Zias, 1982). Recently four skulls with large trephinations were recovered in the area of Qaranthal, increasing the number of trephined skulls from this site to eight (J. Zias, personal communication). Two other crania with holes may be pseudo-trephinations : one is from the cemetery near the Qaranthal, (Hachlili et al., 1981), the other is from Yavne Yam on the coastal plain site near Jaffo (Kaplan, personal communication) ; these are dated between 36 B.C. and 70 C.E., (*see Table I*).

Some indirect literary evidence concerning the practice of trephination by Roman-Syrian « physicians » who professed to « cure blindness by opening the brain and removing worms », is reported by Lisowski (1967).

Interestingly, trephination is rarely mentioned in ancient Jewish sources, such as the Bible or the Talmud. In the latter a reference is given (Git. 56 b) on a post-mortem opening of the brain-case namely that « something like a sparrow or dove was found in Titus' head » (Sussman, 1967, p. 210). This Talmudic commentary, however, seems to be more a reflection on the man who commanded

TABLEAU I. — Trephinations in Israel and South Sinai by type, healing status and period.

<i>Site</i>	<i>Number</i>	<i>Type</i>	<i>Healing status</i>	<i>Period</i>
South Sinai	1	Rounded	+	Chalcolithic
Azur	1	Rounded	+	Chalcolithic-E.B
Arad	1	Rounded	+	Early Bronze
Jericho	1	Rounded	+	Neolithic
Jericho	2	Rounded	+	Middle Bronze
Lachish	3	Angular	-	Iron Age
Lachish	2	Rounded	+	Iron Age
Timna	1	Angular	-	Iron to Roman
Acco	1	Rounded	-	Hellenistic
Jericho, Qarantal	8	Rounded	-	Roman*
Jericho, Qarantal	1	Uncertain	-	Roman
Yavne Yam	1	Uncertain	-	Roman

(\*) Dating most probably Roman, but older period can not be excluded.

(+) Traces of healing.

(-) No traces of healing.

the destruction of the Holy Temple rather than a medical observation. Preuss (1978, p. 347) also mentions a disease called Ba'ale Ratham whose symptoms as described in the Talmud were « eye tears, nostril drips, saliva flow and flies swarming around the sick man », treated by a mixture poured upon the patient's head until « the base of the skull is softened and then his brain is cut open ». The insect or tumor is then « lifted up, grasped with a pair of tweezers and burned ».

Ancient Talmudic sources (Tosefta Oholoth 2 : 3) describe a borer for drilling holes on the skull, and a case of trephination where « the skull deflected was later covered with the dried shell of a pumpkin », as is done today by island dwellers using cocount shells according to Preuss (1978, p. 205).

The reasons for trephination in prehistoric to present times, among different peoples and cultures, are multiple. Hippocrates, as many other scholars after him, believed trephination was done for the relief of skull pressure on the brain, and was probably related to cranial trauma. Broca (1876) considered trephination was often practised to cure mental disorders. Religious beliefs or « fetishism » may also be a factor in present-day trephinations among some « primitive » groups. Thus, Margetts (1967), found in Africa not only prophylactic trepanning but also a widespread use of cranial rondelles as amulets to protect against spirit intrusion in the body. According to Ruffer (1918), cranial bone powder was thought by some « to possess curative properties ».

Two surgical methods used in trephination have been described in detail by Margetts (1967), namely round and angular incisions. At the site of ancient Lachish in Israel, both techniques are found in trephined crania. The rounded type is « clinically » more effective, according to the number of « healed » cases

found. Indeed, two crania from Lachish with angular trephinations show no sign of a healing process whereas all the « round » trephinations present smooth borders indicative of post-operative healing and probably recovery and survival. Likely enough the « statistics » of the less effective angular procedure in terms of survival was known to the « physician » and people of Lachish during the Iron period. In this connection, a pertinent observation by Brothwell (1965) may be cited, namely « The surgical procedure suggests different surgical traditions at Jericho and Lachish ». That is, the presence of both types of surgical procedures at Lachish strongly suggests the possibility of a *choice* rather than an imposed tradition, in the performance of the trephination, perhaps according to the « diagnosis » of the ailment and/or the religious belief of the patient or practitioner. We can not exclude the possibility that the angular type of trephination was performed post-mortem and not only on living individuals as is the case with the healed round holes (*fig. 1a and 1b*).

## 2) Artificial cranial deformation

Deformation of the head in the living is a very old, if not the most ancient, cultural practice leading to changes in one's natural morphology. It was familiar

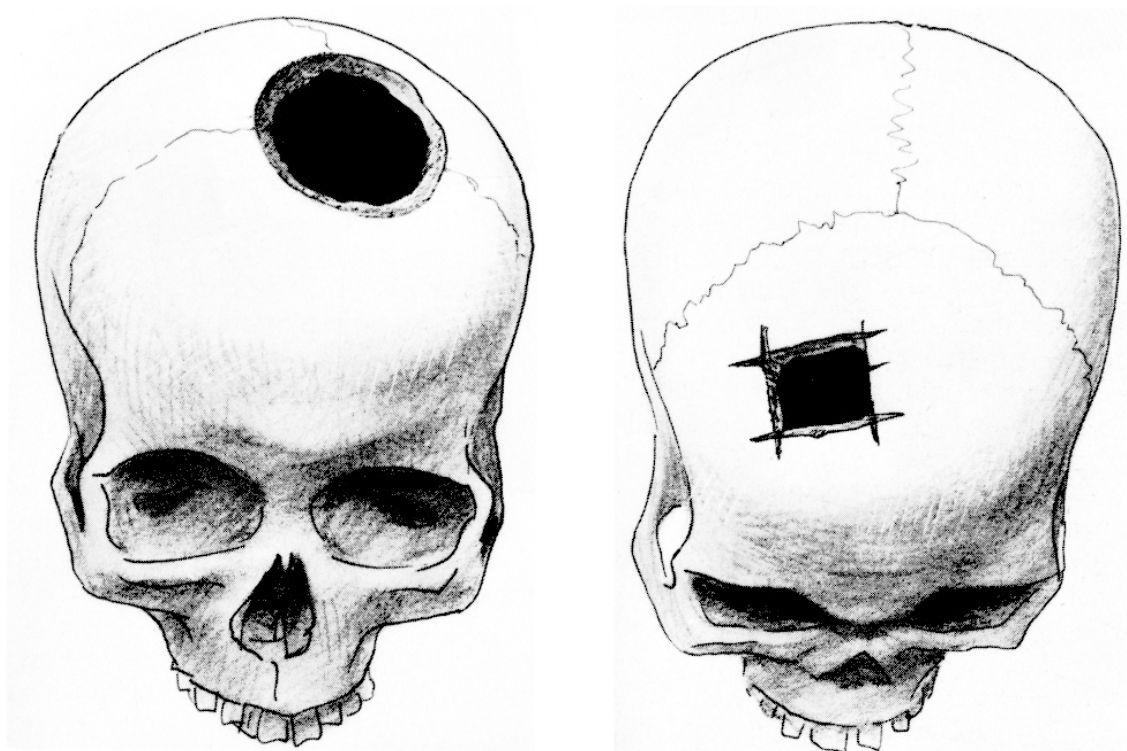


Figure 1. — Trephinations : 1a) Round trephination, Jericho, Qarantal ;  
: 1b) Angular trephination, Timna.

to Hippocrates who described how « among the longheads, as soon as a baby is born its head is moulded by hand and later by the use of bandages and appliances until it becomes drawn out in a unique fashion » (Wells, 1964, p. 163).

Trinka (1983) goes back to the Middle Palaeolithic in suggesting that artificial cranial deformation occurred among the Mousterian people from Shanidar in Iraq. During the Neolithic (ca. 10 000 B.P.) and Chalcolithic (ca. 6 000 B.P.) cases of unquestionable cranial deformation appear at various sites in the Middle East : for example, in Israel (Kurth and Rohrer-Ertl, 1981), Syria (Ferembach, 1970), Cyprus (Angel, 1953), Turkey (Senyurek and Tunakan, 1951), Lebanon (Ozbek, 1974). According to Menard (1977), artificial deformation of the head appears to have been relatively common also in the European Neolithic. Apparently the most fertile social milieu in which the practice of cranial deformation flourished was undoubtedly in the Americas, with an incidence of 90 % of the total population in some regions (Dingwall, 1931 ; Wells, 1964).

This cultural custom appears all over the world with the possible exceptions among Australian aborigines, Chinese and Egyptians. The Nile region in Egypt has been the richest in the recovery of ancient human remains, including mummified corpses, yet cranial deformation in the Valley is also a relative rarity ; the most ancient deformed skull found in Egypt belongs to the sixth century C.E. Artistic representations, however, especially during the reign of Akhenaten in the 18th Dynasty, do show the King, members of his family, and officials manifesting extremely deformed heads. However, the mummified corpse of the King that was studied showed an unusual form of acromegalic or macrocephalic disease, and it has been suggested that the morphology of the Pharaoh's head « inspired » the Egyptian artists of the time to « draw » the same cranial form of the King in the portraits of his close associates (Dingwall, 1931).

Some groups still practice or have only recently abandoned head deformation. The Mangbetu tribe in Zimbabwe, for example, use head-moulding in the infant as a prerogative of nobility. In France the custom survived as late as the end of the 19th century among some of the lower social classes, here too reflecting a class distinction. Indeed, according to Dingwall (1931) in Asia Minor, Kurdistan and India, head deformation is still linked to high social status.

In the Celebes and Borneo and among some of the Maronites in Lebanon, cranial deformation is the result of strapping the newborn onto a cradle with a special attachment designed to apply front — to back pressure on the head, a practice that « prevents (the infant) from being stifled when it is being carried about in its mother's arms » (Lortet, 1884). Lortet also found cranial deformation in Phoenician skulls, and noted that « the transverse diameter is (thereby) augmented and the living inhabitants around Tyre and Sidon (in Lebanon) show on their heads a distortion of similar type ».

Among the Lebanese Maronites who emigrated to America and discontinued the practice, the occipital flattening and hyperbrachycephaly of the head have completely disappeared in the American-born first generation (Ewing, 1950).

A suggestion was that the beginning of artificial cranial deformation was linked to the first appearance of brachycephaly during the Upper Palaeolithic period and a desire of prehistoric men to continue with a preceding « longhead tradition » (Zivanovic, 1982).

In regard to the Middle East, according to Dingwall (1931), there is no satis-

factory confirmation that artificial head deformation was practiced in ancient Chaldea, Babylonia, or Assyria, although he does accept that artificial deformation of the head may be discerned in a tomb monument at Marash, northern Syria, which shows two persons engaged in a ceremonial meal. Dingwall also believes that the ancient Hittites in the Middle East practiced head deformation, although no evidence is provided (see also Ferembach, 1985).

The only reference available on cranial deformation among recent Jews is that of Dingwall (1931) who found « head deformation produced by the application of wads, pads and bandages to the head is prevalent throughout the Tiflis area among Armenians, Jews, Greeks and Ossetes, and the result is to flatten the forehead ».

After the Neolithic period, the only references to cranial deformation in the region are those cited by Risdon (1939) at Lachish (*fig. 2*) and by Meigs (1859) in crania from a quarry-cave in Jerusalem. Cranial deformation in Israel was, till the Roman period, extremely rare and seems to have been an imported feature. To our knowledge, there is no evidence that the Canaanites, Israelites or Philistines customarily performed this kind of head mutilation.

This section may be concluded with a word of caution. Deformed skulls not infrequently are found in archaeological excavations as a result of burial conditions, and these may be confounded with artificial deformation.

Illustration non autorisée à la diffusion

Figure 2. — Cranial deformation, Lachish (photograph from C.B. Stringer, British Museum N.H.)



## II. — DISCUSSION

The practice of surgery became fairly widespread only in the Hellenistic — Roman world, including the Middle East, with Hippocrates (5th century B.C.E.), Celsus (1st century C.E.) and Galen (2nd century C.E.). Celsus, for example, described a large variety of surgical interventions performed in the « medical school » of Alexandria, such as excision or treatment of tumors, aneurysms, hernia, abscesses of the liver, removal of stones in the bladder, plastic surgery, amputations, resection of bone including the lower jaw, etc. (Celsus, translated by Spencer, 1948 ; Ackerknecht, 1967).

The techniques of trephination during the Roman period and the surgical instruments used have been described in some detail by Milne (1907) and Sacks (1952). The trephine instrument (also called *terebra serrata*) was a cylindrical piece of metal with a serrated cutting edge and a movable central pin rolling in between the palms of the hands. The Greek trephine (Latin *modiolus*) was to be plunged into cold water to prevent injury of the bone by heat. Forceps and chisels were also used, some of them especially created to avoid injuries of the meninges. Indeed, the ancient Greeks and Romans apparently « developed the art of trephining to a high degree of perfection » (Walker, 1951).

It may be noted again that, although trephination apparently occurred in Israel during the Greco-Roman period of ca. 100 B.C.E.-100 C.E. (Zias, 1982), it is doubtful whether such was practised among the Jews or that Jewish physicians were involved in this medical « treatment » even among non-Jews. To be sure, a very large Jewish community lived in Alexandria at the time, including many Jewish physicians (Allbutt, 1921, p. 143) and it is likely that the techniques of trephination achieved by the Greeks, Romans, Syrians and Egyptians in this large medical center were also known to the Jewish doctors.

There is little archaeological information concerning the charnel-cave found near the Qarantal in Israel, in which eight trephined crania (of many normal skulls) were found (Zias, 1982). If this cave can be considered a part of the very large Jewish cemetery excavated by Hachlili et al. (1981), then there is here real evidence that trephination was practiced at least to some extent by Jews in the Roman period, perhaps among the Essenians as suggested by Dajani (1963).

The round hole on the skull found at Hellenistic-Roman Acco (Goldman, 1961) was undoubtedly made by the same kind of instrument described by Hippocrates, namely the *terebra serrata*. Probably it had not been necessary, in this specific case, to enlarge the small cavity since the operation apparently came to an end with the death of the individual, leaving the original marks of the instrument. Unfortunately nothing in this particular tomb provides any information about culture — religious or national.

The kind of cranial trephination found at the site of Timna in the Negev, which refers to sometime between the end of the Iron Age and end of the Roman period, is of the angular type (Ferembach, 1957), similar to the trephination in two of the skulls from Lachish. Hence it differs from the round trephining found in all the Hellenistic — Roman specimens. As previously noted the angular trephination especially appears to be associated with a very low rate of survival, indicated by lack of healing of the wound in the skull, and may have been practiced for ritual rather than for therapeutic reasons. Ferembach has remarked that

the Lachish and Timna trephinations were identical with those found in North Africa in the 3rd century B.C.E. dolmens of Roknia and in modern Berber crania from the Aures mountains.

Concerning artificial cranial deformation, our reexamination of the crania from Lachish strongly indicates that at least some of the skulls described by Risdon (1939) as artificially deformed, actually present a normal, undeformed cranial shape commonly found among diverse populations of the Middle East. In only one skull from Lachish is the retreated frontal bone associated with a post-coronal transverse groove that suggests bandage marks indicative of artificial deformation, (*see fig. 2*). In fact, the incidence of cranial deformation in the entire ossuary of Lachish was actually very low (ca. 1 %) whereas among groups normally practicing cranial deformation, the whole population tended to be involved (e.g. Armenians, Maronites, Pueblo Indians, etc.)



Figure 3. — Natural « trigonocephaly », Nahal Hever Israël

It may be relevant to mention that among Jewish remains in Israel from the Hellenistic to Byzantine periods (i.e. En Gedi, Yavne Yam, Jericho, unpublished material), a very unusual and characteristic cranial shape is sometimes found (*see Fig. 3*). The crania are very short antero-posteriorly, have an extremely narrow frontal width, and a wide biparietal diameter that, viewed from above gives the calvarium a triangular shape. This apparently normal « trigonocephaly » has hitherto not been described in the Lachish remains or in Bedouin remains from the Negev, and is to be distinguished from the pathological condition resulting from premature obliteration of the coronal suture.

### III. — CONCLUSIONS

According to the present review, head deformation in the ancient Middle East was practiced during relatively short intervals of time and was limited to a few sites, e.g. the Neolithic at Jericho and Khirokitia, and the Chalcolithic at Byblos and Seyh Hoyuk. Subsequent to the Neolithic, cranial deformation became rare and appears only at the Iron Age site of Lachish and probably in the Roman period in Jerusalem.

The oldest cases of skull trephination in the Middle East are found in the Chalcolithic and Early Bronze Age periods in Israel, although one Neolithic case of trephination from Jericho has been reported. An angular type of trephination, different from the round kind usually found in the region, appears in Iron Age Lachish, and also somewhat later in a Hellenistic — Roman tomb at Timna. The largest number of crania with trephination, however, occurs during the Roman period in the area of Qarantal, in the Jordan Valley; here all the trephinations were of the round type, and most of these manifested healed borders.

Contrary to the round, healed incisions apparently made for therapeutic reasons, the angular trephinations seem to be of a ritual nature. This last type, found in Israel infrequently only at two sites, is reported to be relatively common in the North of Africa from the Iron Age to present times. It is suggested here that the cranial deformation found at the Lachish Iron Age site, as well as the angular kind of trephinations at this site indicate intrusive cultural practices, probably of African origin.

During the Pre-Pottery Neolithic period in the Middle East, numerous cultural transformations occurred, some of them involving direct human manipulations of the skeleton, such as removing the skull for decoration and plastering (Ferembach and Lechevallier, 1973; Arensburg and Hershkovitz, 1988; Yakar and Hershkovitz, 1988). Too, according to Kurth and Rohrer-Ertl (1981), one of the Neolithic skulls from Jericho was trephined and plastered. This latter early « treatment » of the skull suggests that trephination and cranial deformation actually developed during the Neolithic at various places in the Middle East as a consequence of the marked socio-cultural and religious changes that occurred in this area of the world during the passage from dependant hunter — gatherers to a relatively independent agricultural economy.

Subsequent to the Neolithic, traditions of trephining and cranial deformation seem to have been discontinued in the area. Hence, the Iron Age Lachish cranial deformation and trephinations, as mentioned above, were probably intru-

sive and not a « rebirth » of old ancestor customs. The cranial deformation at this site, for example, gives to the skull an elongate contour very similar to that of the Egyptian Akhenaton King while all the Neolithic deformations gave the skull a rounded, short and low shape. As previously mentioned, the angular trephinations during the Iron Age were different than those of earlier and later times not only in shape but also in the surgical techniques used and healing expectations.

The ancient practice of artificial cranial deformation disappeared from most parts of the Middle East in the later Hellenistic and Roman periods, but not so cranial trephination that reached its maximum frequency, especially in the Jordan Valley during the Roman period in Israel (*see Table 1*).

#### ACKNOWLEDGMENTS

*We are grateful to Max and Utah Levkovitz Foundation for their financial support ; to Ch. Stringer of the British Museum (Natural History) for his kind permission to study the material from Lachish ; to professor M.S. Goldstein for his helpful advice and comments ; and to A. Pinhasov for the photographs.*

#### BIBLIOGRAPHY

- ACKERKNECHT (E.), 1967. Primitive Surgery, in D. Brothwell and A.T. Sandison (eds), *Diseases in Antiquity*, Springfield, Ill, Thomas, pp. 635-650.
- ALLBUTT (T.C.), 1921. *Greek medicine in Rome*, Macmillan and Co London.
- ANGEL, (J.L.), 1953. The human remains from Khirokitia, in : P. Dikaios, *Khirokitia 1936-1946*, Oxford University Press.
- ARENSBURG (B.) and HERSHKOVITZ (I.), 1988. Nahal Hemar cave, Neolithic human remains. *Atiqot* 18 : 50-58.
- BATRAWI, (A.), 1935. Report on the human remains. *Mission archéologique de Nubi, 1929-1934*, Cairo.
- BROCA (P.), 1876. Sur l'âge des sujets à la trépanation chirurgicale néolithique. *Bull. Soc. d'Anthrop. Paris*, 11 : p. 572.
- BROTHWELL (D.R.), 1965. The palaeopathology of the EB-MB and Middle Bronze Age remains from Jericho (1957-1958, excavations), in : K.M. Kenyon, *Excavations at Jericho, vol. 2*, British School of Archaeology in Jerusalem, pp. 685-693.
- DAJANI, 1963. Chronique archéologique. *Revue biblique*, 70, pp. 421-422.
- DINGWALL (E.J.), 1931. *Artificial cranial deformation : A contribution to the study of ethnic mutilations*, Bale and Danielsson, London.
- EWING (J.F.), 1950. Hyperbrachycephaly as influenced by a cultural conditioning. *Papers Peabody Museum, Mass.*, 23 (2), p. 99.

- FEREMBACH (D.), 1957. A propos du crâne trépané trouvé à Timna, origine de certaines tribus Berbères. *Bull. Mém. Soc. Anthr. Paris*, 8, pp. 244-275.
- 1970. Etude anthropologique des ossements humains néolithiques de Tell-Ramad, Syrie. *L'Anthropologie* 74, pp. 244-275.
- 1985. Quelques coutumes et modes préhistoriques intéressant le crâne. *Arqueologia* (Porto), 12, pp. 47-56.
- FEREMBACH (D.), LECHEVALLIER (M.), 1973. Découverte de crânes surmodelés dans une habitation du VII<sup>e</sup> millénaire à Beisamoun, Israël. *Paleorient*, 1, pp. 223-230.
- GHANNAN. 1963. Chronique archéologique. *Revue biblique*, 70, pp. 421-423.
- GOLDMAN (Z.), 1961. Surgical trepanation in ancient times. *Bull. Isr. Exploration Soc.*, 25, pp. 258-260 (in Hebrew).
- HACHLILI (R.), ARENSBURG (B.), SMITH (P.) and KILLEBREW (A.), 1981. The Jewish Necropolis at Jericho. *Current Anthropology*, 22, pp. 701-702.
- HERSHKOVITZ (I.), 1987. Trephination : The earliest case in the Middle East. *Mitekufat Haeven, Journal Israel Prehistoric Soc.*, 20, pp. 128-135.
- HRDLICKA (A.), 1987. Trephining in Mexico. *Am. Anthropologist*, 10, pp. 389-396.
- JONES (W.H.S.), 1923. *Hippocrates : Works (translation)* Heinemann (Loeb Library), London.
- KURTH (G.) and ROHER-ERTL (O.), 1981. On the anthropology of the Mesolithic to Chalcolithic human remains from the Tell es-Sultan in Jericho, Jordan in : K.M. Kenyon, *Excavations at Jericho, British School of Archaeology*, Jerusalem, pp. 407-499.
- LISOWSKY (F.P.), 1954. A report on the skulls from excavations at Sesebi (Anglo-Egyptian Sudan). *Actes IV<sup>e</sup> Congr. Intern. Sc. Anthropol. et Ethnol.*, Vienne, pp. 1-228.
- 1959. Agyptische Trepanationen. *Homo suppl.* 6, p. 147.
- 1967. Prehistoric and early historic trepanations, in : D. Brothwell and A.T. Sandison (eds), *Diseases in Antiquity*. Springfield, t. 11, Charles C. Thomas, Chapter 52, pp. 651-672.
- LISOWSKY (F.P.) ASHTON (P.) and ORMEROD (J.F.), 1957. The skeletal remains for the 1952 excavation at Jericho. *Z. Morph. und Anthropol.*, 48, pp.126-150.
- LORTET (L.), 1884. Cause des déformations que présentent les crânes des Syro-Phéniciens. *Bull. Soc. Anthropol. de Lyon*, 3, pp. 30-40.
- MALLIN (R.) and RATHBUN (T.A.), 1976. A trephined skull from Iran. *Bull. of the New York Acad. of Medicine*, 52, pp. 782-787.
- MARGETTS (L.), 1967. Trepanation of the skull by the medicine-men of primitive cultures, with particular reference to present-day native East African practice, in D. Brothwell and A.T. Sandison (eds) ; *Diseases in Antiquity*, Charles C. Thomas, Springfield, t. 11, pp. 673-701.
- MEIGS (J.A.), 1859. Description of a deformed, fragmentary human skull, found in an ancient quarry-cave at Jerusalem, Philadelphia.
- MENARD (J.), 1977. Etude craniologique et odontologique de Mérovingiens adultes du Vexin français. *Bull. Mém. Soc. Anthr. Paris*, 4, pp. 229-243.
- MILNE (J.S.), 1907. *Surgical instruments in Greek and Roman times*. The Clarendon Press, Oxford.
- OAKLEY (K.P.), BROOK (M.A.), KESTER (A.R.) and BROTHWELL (D.R.), 1959. Contribution on trepanning or trepanation in ancient and modern times. *Man*, 59, pp. 93-96.

- OZBEK (M.), 1974. A propos des déformations crâniennes artificielles observées au Proche Orient. *Paleorient* 2, pp. 469-476.
- PARRY (T.W.), 1936. Three skulls from Palestine showing two types of primitive surgical holing. *Man*, 36, pp. 170-171.
- PATRICK (A.), Diseases in the Antiquity, Ancient Greece and Rome, in : D. Brothwell and A.T. Sandison (eds). *Diseases in Antiquity*, Springfield, t. 11, Charles C. Thomas, pp. 238-246.
- PREUSS (J.), 1978. *Biblic and Talmudic Medicine*. Sanhedrin Press, N.Y.
- RIDSON (D.L.), 1939. A study of the cranial and other human remains from Palestine excavated at Tell-Duweir (Lachish) by the Wellcome-Marsron Archaeological Research Expedition. *Biometrika*, 31, pp. 99-166.
- RUFFER (M.A.), 1918. Studies in palaeopathology : some recent researches on prehistoric trephining. *J. Path. Bact.*, 22, p. 90.
- SACKS (E.), 1952. *The history and development of neurological surgery*. Paul, B. Hoeber, Inc. N.Y.
- SENYUREK (M.S.), 1958. A case of trepanation among the inhabitants of the Assyrian trading colony at Kultepe, Anatolia, 3, pp. 51-53.
- SENYUREK (M.S.) and TUNAKAN (S.), 1951. Seyh Hoyuk iskeletleri. *Belleten*, 15, pp. 431-445.
- SPENCER (W.G.), 1948. *Celsus : De Medicina (translation)*. Heinemann (Loeb Library), London.
- STEWART (T.D.), 1958. Stone Age Skull Surgery. *Smithsonian Report for 1957, Washington (D.C.)*, pp.469-491.
- SUSSMAN (M.), 1967. Diseases in the Bible and the Talmud, in D. Brothwell and A.T. Sandison (eds) ; *Diseases in Antiquity*, Springfield, t. 11, Thomas, p. 210.
- TRINKAUS (E.), 1983. *The Shanidar Neandertals*. Academic Press, N.Y.
- WALKER (E.A.), 1951. *A history of neurological surgery*. The Williams and Wilkins Co., Baltimore.
- WELLS (C.), 1964. *Bones, bodies and disease*. Thames and Hudson, London.
- WOOD-JONES (F.), 1910. Fractured bones and dislocations, in : G. Elliot-Smith and F. Wood-Jones (eds). *The Archaeological Survey of Nubia, Report for 1907-1908, vol. 2, Report on Human Remains*, pp. 293-342.
- YAKAR (R.) and HERSHKOVITZ (I.), 1988. Nahal Hemar cave, The modelled skulls, *Atiqot* (in press).
- ZIAS (J.), 1982. Three trephinated skulls from Jericho *Basor* 246, pp. 55-58.
- ZIVANOVIC (S.), 1982, *Ancient Diseases*, Methuen and Co Ltd London.

---

Reçu le 4 mai 1988 ; accepté le 27 juin 1988.