

# Chirurgica Taurina: A 10-Year Experience of Bullfight Injuries

Udo Rudloff, MD, Victor Gonzalez, MD, FACS, Eduardo Fernandez, MD, FACS, Esteban Holguin, MD, Gustavo Rubio, MD, Jorge Lomelin, MD, Michael Dittmar, MD, and Rafael Barrera, MD

**Background:** Despite recent efforts to improve medical treatment for injured bullfighters, including the foundation of a scientific society for bullfight injuries, serious injuries, in particular in villages and smaller arenas, still do occur. We are not aware of any series in the English literature that aimed to study the specific mechanisms, types, and outcomes of these injuries.

**Methods:** A review of the trauma registry of injured bullfighters who suffered any type of trauma during bullfighting and received emergency therapy by the Surgical Trauma Services between 1994 and 2004 at the Plaza de Toros Nuevo Progreso, Guadalajara, Mexico.

**Results:** In all, 68 out of 750 bullfighters (9.06%) required emergency assistance during bullfighting. Trauma to the upper and lower extremity was most common (66%), followed by injuries to the inguinal (8%) and perineal area (7%). Extremity injuries included penetrating wounds requiring operative debridement in 64% of cases, articular dislocations in 4%, closed fractures in 4%, and open fractures in 1% of cases. Major vascular injuries occurred in 5% of the cases. Penetrating inguinal and penetrating perineal injuries were associated with major vascular injuries to the femoral vessels, necessitating operative repair in 33% of the cases.

**Conclusion:** A considerable risk of serious, life-threatening injuries is inherent to bullfighting. Penetrating inguinal and perineal trauma with injury to the femoral vessels represents a specific, potentially fatal injury. A low threshold for exploration of these penetrating injuries in injured bullfighters is associated with a favorable outcome. Appreciation of the unique mechanisms and types of injuries related to bullfighting should lead to target intervention and help the evolution of improved emergency treatment in organized bullfighting.

**Key Words:** Injury, Bullfighting, Groin, Perineum.

*J Trauma.* 2006;61:970–974.

Bullfighting continues to be a popular, deeply traditional celebration of the unique culture of many Ibero-American countries. While bullfight arenas in larger cities are nowadays equipped with emergency facilities, including fully furnished operating rooms, the majority of bullfighting still takes place in smaller arenas or villages in the countryside often far away from advanced medical and surgical support.

Bullfighting, in its true nature, follows three principles. The bullfighter (*matador*) first aims to hold his ground against the animal, then commands the bull by controlling the speed and directions of its movements, and finally tempers him. The *matador*, standing with closed feet in front of the attacking animal, being certain to lead the bull into the desired direction, ultimately symbolizes the ability of man to overrule instinct driven sheer force. During the celebration of bullfighting (*fiesta*) the *matador* is supported by his *banderilleros* who hook small flags with sharp hooks (*banderillas*; 70 cm in length with 6-cm large hooks) into the back of the

bull's neck, and the *picadors* who ride on protected horses and injure the animal with a *puya* (long, sharp lance) in the same area. Both injuries cause pain to the animal when raising its head. They aim to prevent the bull from attacking the *matador* with a raised head keeping the horns at a low level (*permitiendo la lidea*), thus reducing the risk of serious injury to the bullfighter.

Injury and death are inherent to the nature of bullfighting. The lack of training of amateur bullfighters might pose an additional threat in this group for serious injuries to occur. Since bull and bullfighter are in unique, repetitive positions to each other, certain body sites of the bullfighter are at an increased risk of being injured. Thus, emergency medical services for injured bullfighters need to be adept to the unique and characteristic injuries of this professional group. We are not aware of any detailed series in the English literature that studied bullfight injuries. We aimed to study these mechanisms and types of injuries caused by organized bullfighting during a 10-year period at the second-largest bullfight arena of Mexico.

## PATIENTS AND METHODS

Records of injured bullfighters between July 1994 and June 2004 from the Plaza de Toros Nuevo Progreso, the second-largest bullfight arena of Mexico, were collected from the prospective trauma registry database of the bullfight arena. This database records all injured bullfighters who received emergency medical care at the arena. Bullfighters were divided into *matadors*, who are fully trained professional bullfighters, and *novilleros*, who are still in training. Injured bullfighters were brought from the ring to the trauma

Submitted for publication February 10, 2005.

Accepted for publication September 2, 2005.

Copyright © 2006 by Lippincott Williams & Wilkins, Inc.

From the Department of Surgery, Hospital Angeles del Carmen, Guadalajara, Mexico (V.G.C., E.F., E.H., G.R., J.L., M.D.); and the Department of Surgery, Long Island Jewish Medical Center, The Long Island Campus for the Albert Einstein College of Medicine, New Hyde Park, New York (U.R., R.B.).

Address for reprints: Udo Rudloff, MD, Department of Surgery, North Shore – Long Island Jewish Health System, North Shore University Hospital, 300 Community Drive, Manhasset, New York 11030; email: udo\_rudloff@hotmail.com.

DOI: 10.1097/01.ta.0000196871.19566.92

room of the arena (*enfermeria*) by paramedics, where initial assessment and stabilization was performed by a team of at least two general surgeons, one anesthesiologist, one orthopedic surgeon, and one cardiothoracic surgeon. Further personnel included two operating room (OR) nurses, three OR technicians, and paramedics. The trauma bay included an operating area equipped with two anesthesia machines, two field OR tables, two Bovie machines, and fiberoptic headlamps. Oxygen was supplied by large H-cylinder tanks and one field steam sterilizer was available. Data about site of injury, type of injury (blow, thrust, fall), and initial treatment during trauma resuscitation were entered by research officers into the trauma registry, which was a custom-made database (Microsoft Access 97, Microsoft Corporation, Redmond, WA). On the discretion of the attending surgeon, injured bullfighters were transferred after stabilization to the tertiary center, Hospital Angeles del Carmen, for further treatment. Patients were accompanied by one surgeon, one anesthesiologist, and two paramedics using on-premises ambulances dedicated to the transport of injured bullfighters. Research officers followed the hospital course of the bullfighters until discharge recording further details of treatment and outcome into the database.

**RESULTS**

During the 10-year study period, 2,328 bullfights during 388 *corridas* were included. Seven hundred and fifty bullfighters were identified, of which 68 (9.06%) met our study inclusion criteria and required emergency medical care by the surgical trauma service at the Guadalajara Plaza de Toros Nuevo Progreso, Guadalajara. The mean age of the injured bullfighters was 32.5 (28–37) years.

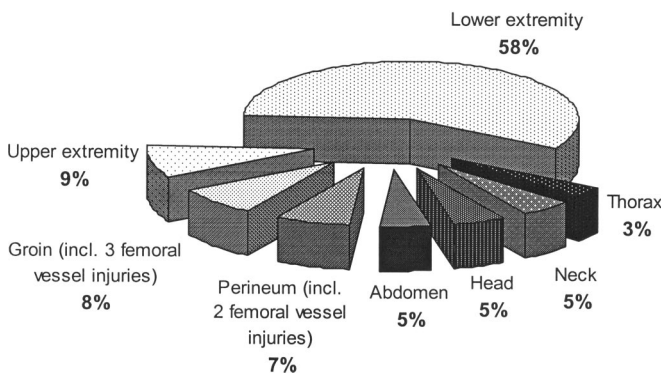
The most common site of injury was the lower extremity (55 of 99 injuries), followed by the upper extremity, the groin, the perineum, and the abdomen (Fig. 1). All groin and perineal injuries were penetrating injuries. Three of the eight groin injuries and two of the seven perineal injuries involved the femoral vessels. Two femoral artery injuries were repaired with vein graft. In one case, the penetrating horn had avulsed the common femoral artery necessitating the deployment of an interposition graft. The two femoral vein injuries were repaired primarily and with vein graft. Of the seven

**Table 1** Extremity Injuries

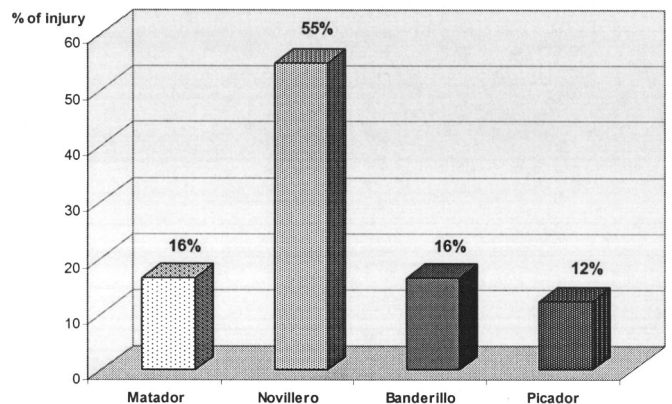
Injury	n
Soft tissue injuries (major, requiring operative debridement)	57
Upper extremity	5
Lower extremity	52
Vascular injuries (requiring operative intervention)	5
Femoral	
Artery	4
Vein	1
Open fractures	1
Upper extremity	0
Lower extremity	1
Closed fractures	4
Upper extremity	4
Lower extremity	0
Articular dislocations	4
Shoulder	4
Total	91

perineal injuries, all involved the scrotum with varying degrees of scrotal hematoma and avulsion of the scrotal skin leaving the testicle bare in one case. There was one case of rectal perforation requiring a diverting colostomy. Of the five abdominal injuries, two breached the peritoneum causing bleeding from the small bowel mesentery in one case, and prolaps of the omentum in the other. In two other cases the bullfighters had separate wounds of entry and exit caused by the horn which had passed tangentially through the layers of the abdominal wall. Of the 71 extremity injuries, the vast majority was penetrating injuries and required operative intervention (Table 1). Wound infection occurred in 7 out of 71 cases of extremity injuries. Six of these occurred in wounds that were primarily sutured (40 cases) even though primary closure was done after apparently adequate debridement, cleaning, and under antibiotic cover. Of the 31 wounds that were secondarily sutured, wound infection developed in only one instance. Reopening and drainage of infected wounds was necessary in one case.

Injuries of the *torero*, the performing bullfighter, were significantly more common than injuries of the *banderillos* and *picadors* (Fig. 2). There was no difference in the severity



**Fig. 1.** Distribution of injuries by anatomic location.



**Fig. 2.** Distribution of injuries under bullfighters.

of injuries between these groups. *Novilleros* had an overall higher incidence of injuries than *matadors* (Fig. 2). The mean hospital stay was 8.5 days (2–15).

## DISCUSSION

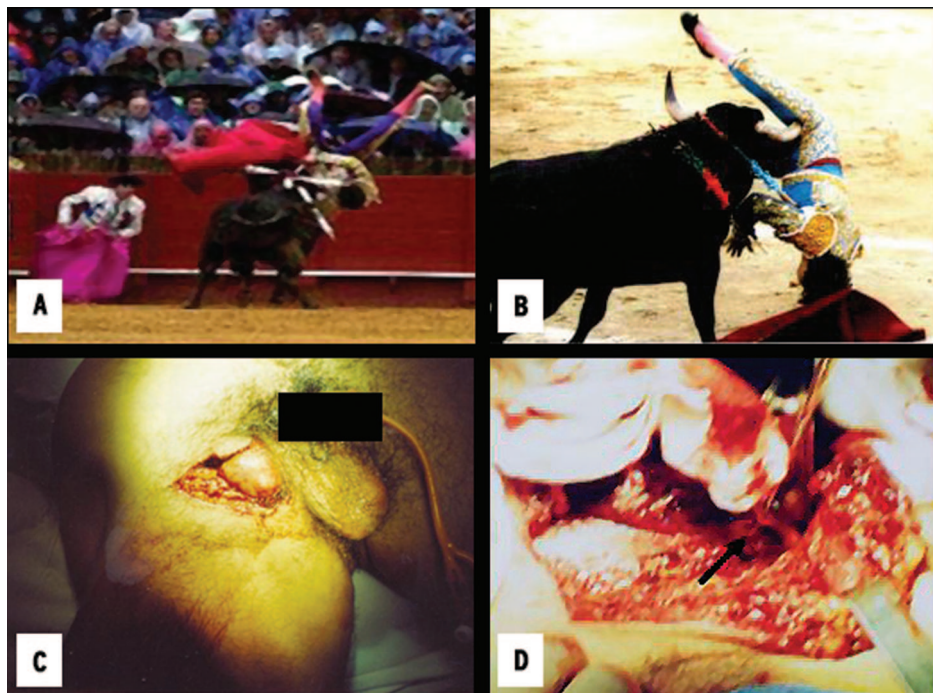Nobody likes to see deaths or serious injuries during bullfighting. When serious injuries occur, they are perceived with deep sadness and grief. The death or injury of a man during the *corrida* represents a negative event within the celebrated ritual. The *fiesta*, however, will continue. To a certain extent, injury and death are inherent not only to the actual contest of bullfighting, but also as a meaning of sacrifice to its true nature and sense. Therefore, bullfighting arenas need to be prepared for the specific and unique injuries of bullfighters. In fact, such medical care for injured bullfighters—named *Cirurgica Taurina*—has started to emerge in the big arenas of Spain and South America during the last two decades.<sup>1,2</sup>

Overall, bullfight injuries are not very common. In this series, 99 injuries occurred during a 10-year period that included 2,328 bullfights. These figures are comparable to a recent review on bullfight injuries in Spain, which recorded 165 injuries during 2,481 bullfights during a 4-year period.<sup>3</sup> The long training and culture of respect for the animal might explain the overall infrequency of bullfight injuries.

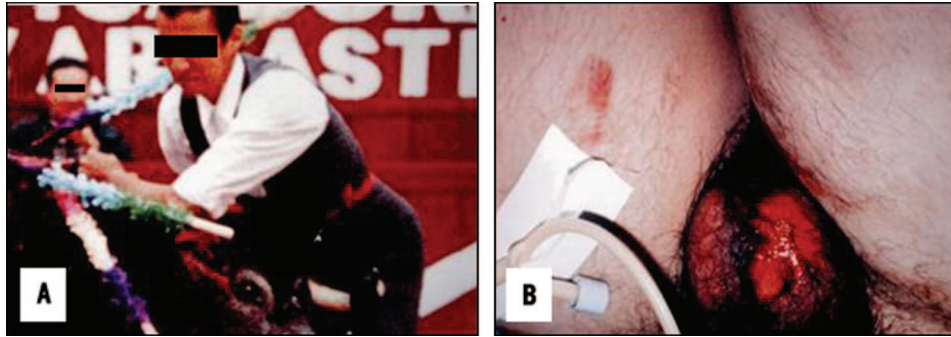
Because bull and *torero* are in certain unique repetitive positions to each other during the contest, one can assume that certain body sites of the bullfighter are more commonly involved in injuries or that a characteristic pattern of injuries

exists. The attacking bull initially approaches the *torero* with its head and horns close to the ground. At the anticipated moment of impact, bulls often tend to suddenly uplift their heads starting an upward stroke, which would most commonly inflict upper thigh, groin, and perineal injuries. The most feared scenario occurs when the initial penetration of the bull's horn is deep enough to air-lift the *torero*. The semicircular upward and sideways path of the bull's horn, exacerbated by continuous repetitive upward blows of the bull's head, leads to a rotating movement of the gored, air-lifted bullfighter. The bull's horn acts hereby as a fulcrum on which the air-lifted bullfighter spins around his own axis. This rotation occurs particularly in the landing phase of such an air-lift, when resulting from the gravity of the rotating body, the *torero* falls back onto the horns of the animal. Because of this rotation, the penetrating horn can make in the bullfighter's wound a turn of up to 180 degrees, causing tremendous wound cavities with tissue destruction and injuries to adjacent structures. Figure 3 shows such a typical air-lift with rotation of the gored bullfighter. This unique mechanism of injury likely contributed to our finding of a 33% incidence of concomitant injuries to the femoral vessels of penetrating inguinal and perineal injuries. Although we did not observe any mortalities, deaths of well-known bullfighters due to avulsion of the common femoral artery have been described.<sup>4,5</sup> This devastating injury occurred once in our series.

Another commonly involved area is the genital region with avulsion of the scrotum or the testicles. *Toreros* attempt



**Fig. 3.** The gored, air-lifted bullfighter spins around his own axis on the animal's horn which has penetrated (A) the left perineum or (B) the right groin. (C) External appearance of right groin bull horn injury shown in B. At right groin exploration (D), a large wound cavity with extensive tissue destruction and injury of the A. femoralis profunda 2 cm distal to its origin (arrow) were encountered.

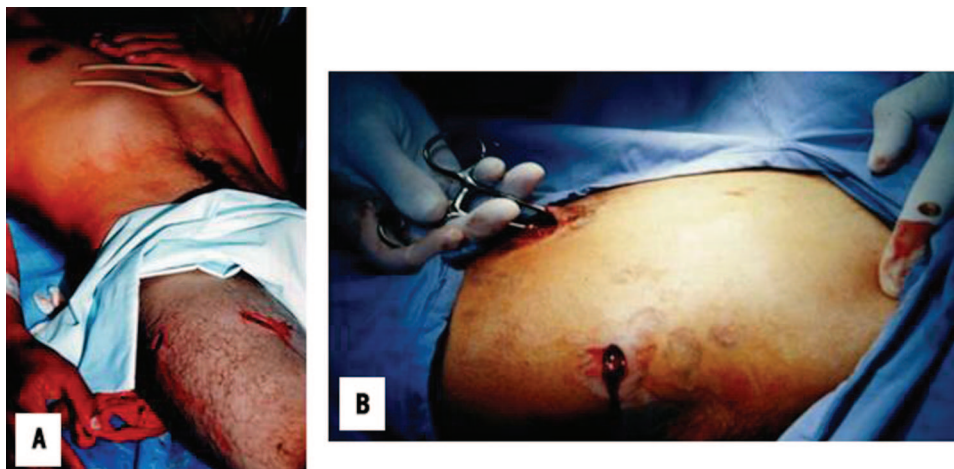


**Fig. 4.** Penetrating scrotal injury (A) during bullfighting. Avulsion of the left hemiscrotum (B) necessitated operative debridement.

to prevent these injuries by wearing tight, smooth trousers on which the horns of the bull more easily slide away. Figure 4 shows a typical scrotal injury after a penetrating blow of an attacking bull. Injuries to the perineum and the gluteal area often occur either during an intentional turn-away move of the *matador* to avoid the passing animal or when attempting to lead a fatigued bull toward the end of the *fiesta* with the *muleta* (red cape). A distracted animal might chase and gore the bullfighter instead of the cape. The entrance wound of these injuries appears often rather small (Figs. 3 and 5). However, the extent of these penetrating injuries can be extensive. For example, a horn penetrating the left gluteal area and perineum might reach to the right buttock as seen in one of our cases. Although all these injuries are per definition penetrating injuries, they are because of the width of the horn and the associated force also always comminuting injuries with significant tearing, contusion, and destruction of surrounding tissue. All these injuries should also be regarded as primarily contaminated wounds. Wound infection was common (11%), especially for wounds that were primarily closed. In wounds closed by secondary intention, the infection rate was low. Therefore, these wounds should be closed secondarily or by delayed primary closure, even when injury is less than six hours old.

Overall, all except two bullfighters returned to their profession. There were no mortalities or permanent disabilities.

Our findings of an disproportionately high incidence of injuries to the inguinal and perineal area, with a significant likelihood of associated injuries to the femoral vessels, supports the concept that these injuries follow a specific pattern due to the inherent nature of bullfighting. The height of the attacking bull's horns at the level of the bullfighter's waist, rotation of the gored and air-lifted bullfighter causing large wound cavities, and the exposed perineal and genital areas to the passing bull's horn are examples of mechanisms of injuries unique to the occupation of bullfighters. Attempts to further reduce injuries during bullfighting should focus on the one side on thorough training of the toreros. On the other hand, the implementation of adequate emergency medical services, including the availability of trauma teams and functional OR's at the bullfight rings, and the opportunity of timely transfer to a higher level of care, after initial stabilization should be mandatory for all large bullfight arenas. This should be extended to smaller bullfight arenas. In rural areas, with longer transport times well equipped and trained mobile surgical teams educated in the recognition and treatment of these injuries should be mandated. Knowledge and increased



**Fig. 5.** The external appearance of penetrating bullhorn injuries (A) often appears small. At right groin exploration, a large hematoma from femoral vein injury was evacuated. Large wound cavity (B) after penetrating lower abdominal injury in the right iliac fossa. At explorative laparotomy, injury of the small bowel mesentery was found.

awareness of the unique mechanisms and types of injuries during bullfighting will lead to a more timely response and focused intervention for this exposed profession.

## REFERENCES

1. Campos Ligastro X. *Traumatología taurina*. 2nd Ed. Mexico: Impresiones Modernas, 1984.
2. Campos Ligastro X. Iatrogenias en heridas por cuerno de toro. *Rev Cir Taurina*. 1988;7.
3. Lehmann V, Lehmann J. Cirugía Taurina—emergency medical treatment of bullfighters in Spain. *Zentralbl Chir*. 2003;128:685–690.
4. Ong S. Bullfighters and their wounds. *World Medicine*. 1973;11:17.
5. Shukla HS, Mittal DK, Naithani YP. Bull horn injury: A clinical study. *Injury*. 1977;9:164–167.